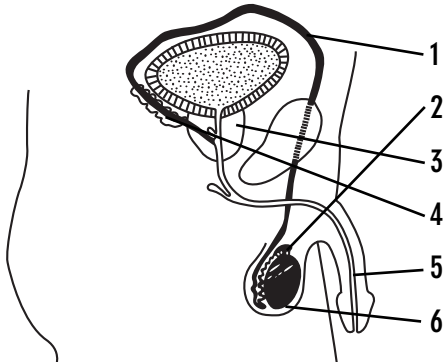


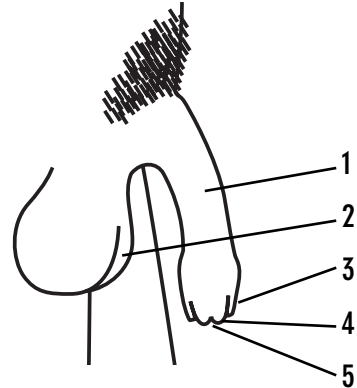
Anatomy and Physiology of Reproduction

Male – Internal



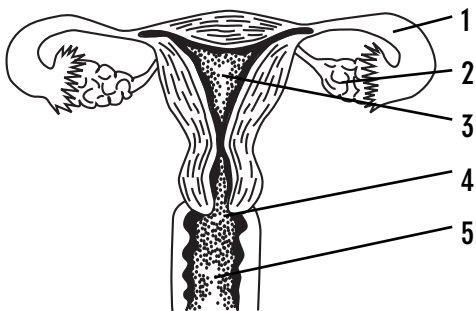
1. Vas deferens
2. Epididymis
3. Prostate gland
4. Seminal vesicles
5. Urethra
6. Testis

Male – External



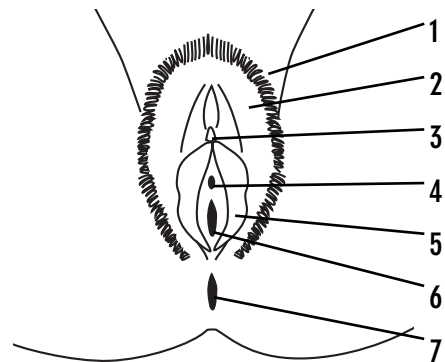
1. Penis
2. Scrotum
3. Foreskin
4. Glans
5. Opening to the urethra

Female – Internal





1. Fallopian Tubes
2. Ovaries
3. Uterus (Womb)
4. Cervix
5. Vagina

Female – External


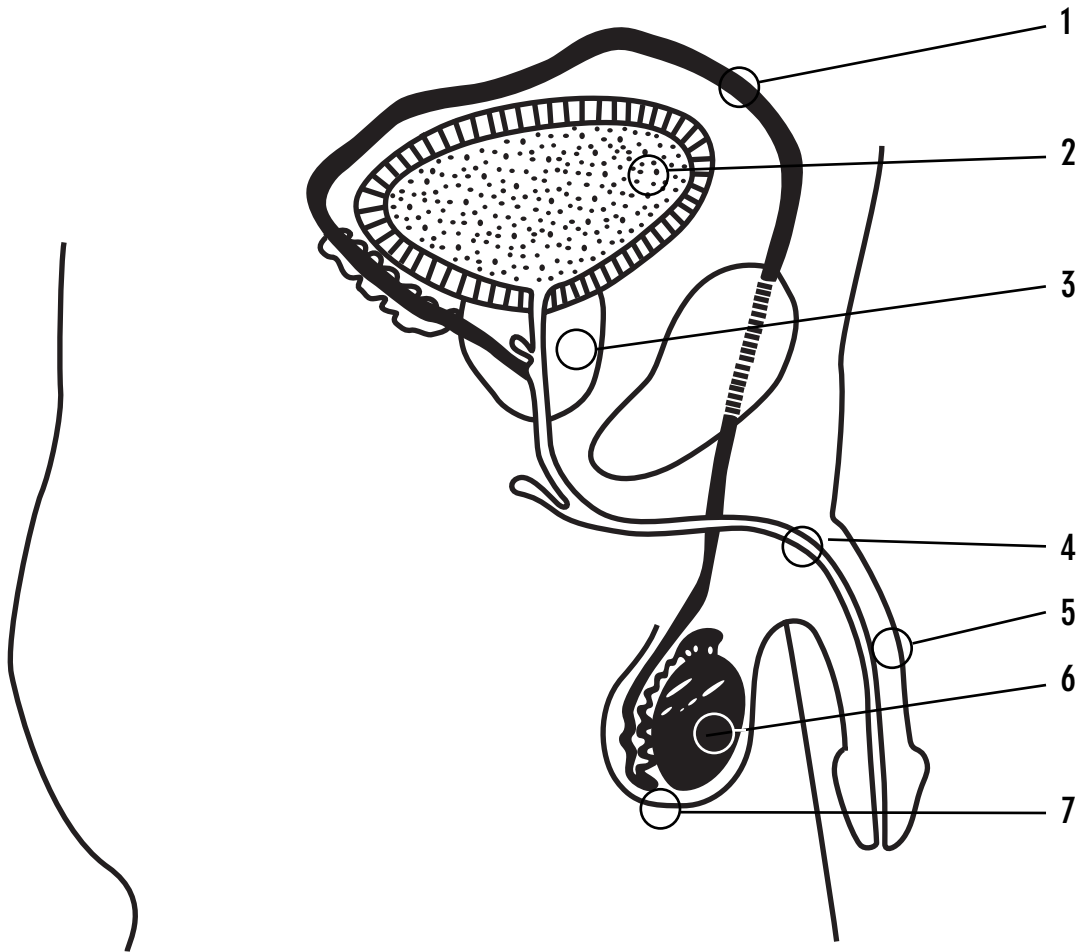



1. Vulva
2. Labia majora (outer lips)
3. Clitoris
4. Opening to the urethra
5. Labia minora (inner lips)
6. Opening to the vagina
7. Anus (not part of the genitals)




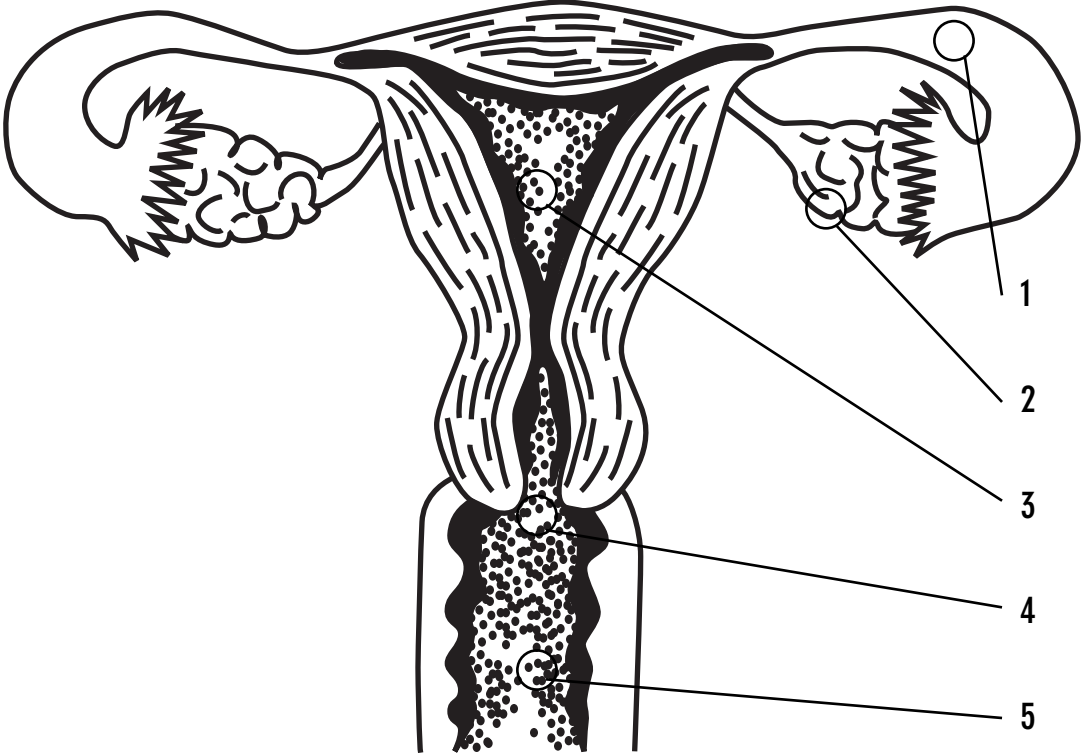



Male Genitals and Reproductive Organs





Female Reproductive Organs





Female Genitals

